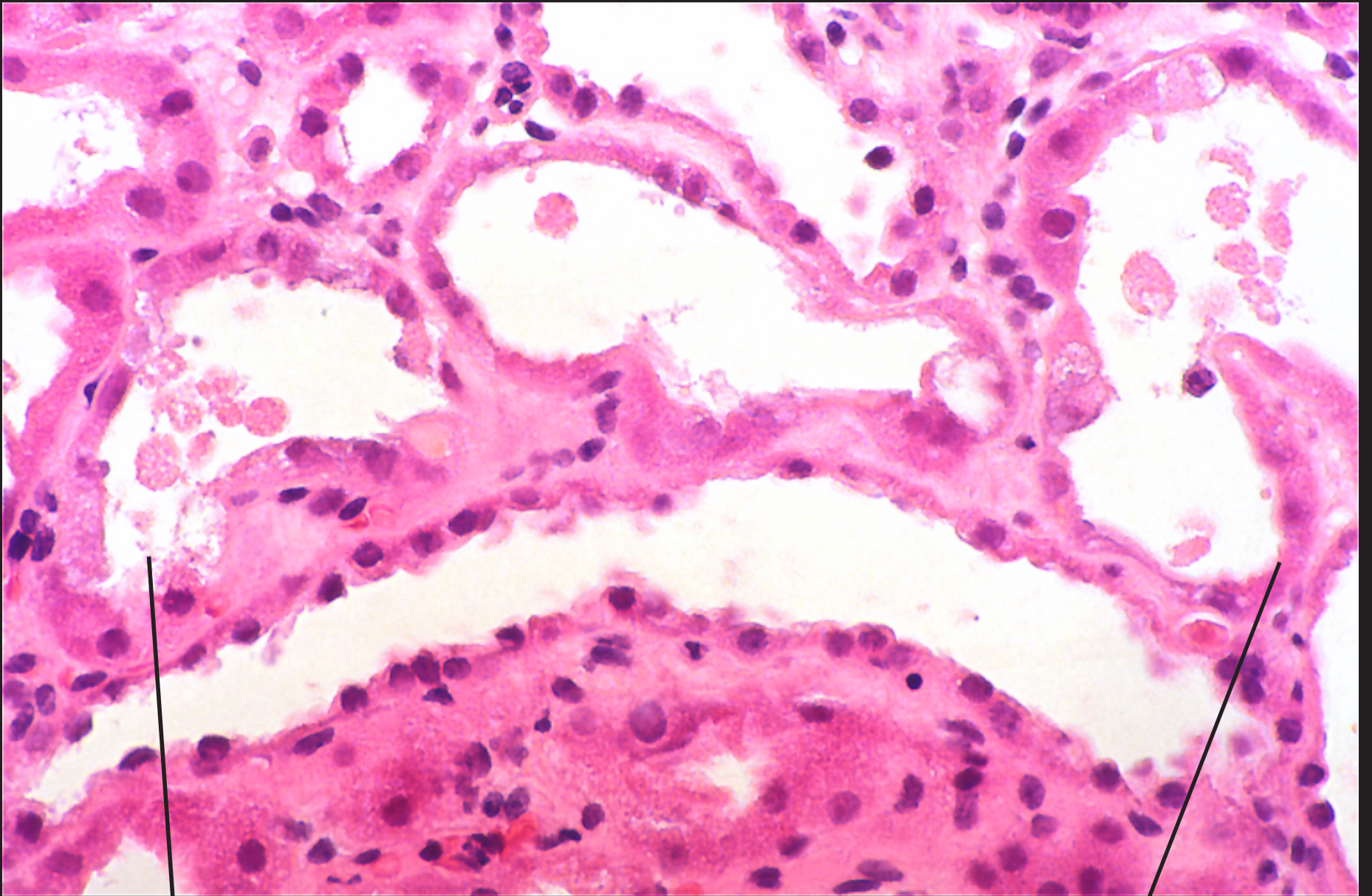


Acute tubular necrosis (H & E stain)

The tubular epithelium has necrosed with cellular debris desquamated into the lumen of the tubule. The tubules themselves are dilated and thinned.



Necrotic cell debris
in tubule lumen

Necrotic epithelium
having lost nucleus